

The role of quantitative computed tomography in the diagnosis of chronic obstructive pulmonary disease

Rolul tomografiei computerizate cantitative în diagnosticul bronhopneumopatiei obstructive cronice

Gabriela Jimborean¹,
Edith Simona Ianoși¹,
Paraschiva
Postolache²,
Oana Arghir³

University of Medicine and
Pharmacy of Târgu Mureș,
Romania

"Grigore T. Popa" University
of Medicine and Pharmacy,
Iasi, Faculty of Medicine, First
Medical Department, Romania

"Ovidius" University of
Medicine and Pharmacy,
Constanța, Romania

Corresponding author:

Edith Simona Ianos
E-mail: ianos_i_edith7@yahoo.com

Abstract

In the last 25 years, there have been important improvements in computed tomography (CT) that may give more details about the lung structure in chronic obstructive pulmonary disease (COPD). The clinical exam and "classic" radiology (chest X-ray, conventional CT) have important roles: they raise the suspicion of hyperinflation, they highlight aspects of pulmonary hypertension, they may detect the triggers of exacerbations, they rule out some COPD complications and other lung diseases that can cause dyspnea (pneumothorax, tumors, bronchiectasis, and fibrosis). The spirometry may confirm the obstructive ventilatory disorder pattern of the disease. The modern CT scan technique - High Resolution CT (HRCT) with Multi-Detector CT procedure (MDCT) gives additional information about morphological details of parenchyma, bronchi, pulmonary vessels or lung function (ventilation/perfusion disorders) without significant lung irradiation. The new techniques provide quantifiable parameters that characterize the emphysema, the main COPD phenotypes and the risk of disease progression. Quantitative volumetric analysis of emphysema provides an early diagnosis of the disease in patients exposed to smoking and pollution. An early personalized diagnostic in COPD offers stronger reasons to prophylaxis by smoking and exposure cessation and an early targeted treatment (inhaled bronchodilators, anti-inflammatory medication, pulmonary rehabilitation, education for lifestyle changes).

Keywords: COPD, emphysema, multidetector CT

Rezumat

Ultimii 25 de ani au înregistrat progrese importante în evidențierea prin tomografie computerizată (TC) a modificărilor ce apar în structura pulmonară în bronhopneumopatia obstructivă cronică (BPOC). Examenul clinic și tehnicile clasice radiologice (radiografia, TC convențională) au un rol important: ridică suspiciunea hiperinflației pulmonare, evidențiază unele aspecte ale hipertensiunii pulmonare, pot detecta factorii declanșatori ai exacerbării, pot elimina unele complicații sau alte afecțiuni ce determină dispnee (pneumotorace, tumori, bronșiectazii, fibroze). Spirometria confirmă disfuncția ventilatorie obstructivă. Tehnicile moderne ale TC (TC de înaltă rezoluție cu funcții „multidetector”) oferă informații suplimentare, de detaliu morfologic, privind parenchimul pulmonar, bronhiile, vasele pulmonare sau chiar aspecte funcționale (tulburările ventilației și ale perfuziei pulmonare), fără a produce o iradiere suplimentară. Noile tehnici pot oferi parametri cuantificabili ce caracterizează emfizemul pulmonar, principalele fenotipuri ale BPOC și riscul progresiei bolii. Analiza cantitativă volumetrică a emfizemului poate asigura un diagnostic precoce al BPOC la pacienți expuși la fumat sau la poluare. Un diagnostic rapid personalizat al BPOC oferă argumente pentru profilaxia bolii prin abandonarea fumatului și a expunerii la poluare și permite un tratament țintit rapid (bronhodilatatoare, antiinflamatoare inhalatorii, reabilitare respiratorie, educație pentru schimbarea stilului de viață).

Cuvinte-cheie: BPOC, emfizem, TC multidetector

Introduction

In the last 25 years, there have been several improvements in computed tomography (CT) that might give more details on the structure of lung parenchyma in chronic obstructive pulmonary disease (COPD), on the main phenotypes or even on lung function. The clinical exam and "classic" radiology (chest X-ray, conventional CT) have important roles: to raise the suspicion of hyperinflation, highlight aspects of pulmonary hypertension, they may detect the triggers of exacerbations, and rule out some complications and other diseases with dyspnea (pneumothorax, tumors, bronchiectasis, tuberculosis, fibrosis, or cardiomegaly). The classical confirmation of the COPD relies on ventilatory obstructive disorder pattern on respiratory function tests (RFTs).

RFTs cannot cover the morphological analysis of the disease and detail the correlation between lesions and lung

function. In the same time, RFTs become abnormal late in the disease evolution and cannot distinguish the very early COPD stage (when the patients are asymptomatic) to provide a targeted prophylaxis.

The primary evaluation of COPD in the pulmonology clinic has to be comprehensive and performed according to several combined criteria (symptoms, COPD Assessment Test, lung function by spirometry/ plethysmography, number of previous year exacerbations, comorbidities, phenotypes characterization)⁽¹⁾.

The modern CT scan technique - High Resolution CT scan (HRCT) with Multi-Detector CT procedure (MDCT) - can offer important additional information to the clinical investigation and RFTs about anatomy of lung parenchyma, bronchi, pulmonary vessels and even about ventilation/perfusion function, without significant lung irradiation^(2,3).

Conventional computed tomography (CT)

Chest X-ray is the first-line imaging technique for pulmonary disease assessment. It is widespread, cheap and everywhere accessible but it is not good enough for emphysema analysis. Chest X-ray has a low resolution and produces images summation effect that gives it a low sensitivity and specificity. A normal chest X-ray cannot rule out emphysema or characterize well enough the different phenotypes of emphysema. Chest X-ray is not considered to be the most accurate tool for identifying lung cancer in COPD patients. Thoracic CT scan became the most efficient imaging method that largely characterizes COPD. CT is not a routine investigation during initial diagnosis assessment. First, diagnosis in COPD relies on clinical features and spirometry.

Thoracic CT will be performed in selected cases upon indication of the pulmonology specialist^(2,4). CT becomes necessary for confirming a specific cause for an exacerbation suspected on a standard chest X-ray or an associated condition (lung tumor, fibrosis, bullae). Thoracic CT is mandatory before lung volume reduction interventions (surgery or unidirectional valves insertion) or to early define some emphysema phenotypes (alpha-1antitrypsin deficit - panlobular emphysema, paraseptal emphysema, association of bronchiolitis or bronchiectasis)^(2,3,5).

The advantages of conventional CT scan compared with standard chest X-ray are multiple in terms of high sensitivity and specificity⁽⁵⁻⁷⁾:

- CT highlights diffuse or localized emphysema (bullae).
- CT can detect small structures/details and analyze the tissue density in the lung parenchyma, bronchi, vessels, chest wall, and mediastinum.
- CT allows detection of aggravating factors (neoplastic diseases, fibrosis, bronchiectasis, cardiovascular comorbidities), triggers of COPD exacerbations or disease complication (pneumonia, pneumothorax, pleural effusion, pulmonary infarction)⁽⁶⁾.
- CT can detect some other respiratory diseases that associate the same symptoms as COPD: dyspnea, cough (sarcoidosis, fibrosis, tuberculosis, silicosis, lung tumors). Kurashima *et al.* showed in 2005 in a study conducted on 516 patients with FEV below 70% that 12.7% of patients had other diseases than COPD⁽⁸⁾.

High Resolution CT/ Multidetector CT

Multidetector CT (MDCT) is an advanced form of computed tomography (CT) technology for diagnostic imaging. In MDCT, a two-dimensional array of detector elements replaces the linear array of detector elements used in typical conventional and helical CT scanners. CT technique is capable to perform quantitative analysis of emphysema, air trapping, airways and vessels. It uses thin slices (0.625 and 1 mm), with three-dimensional (3D) reconstruction, low dose radiation (effective tube current, 30-60 mAs), analysis of lung volumes and attenuation in inspiration and expiration. 3D HRCT is nowadays considered the gold standard technique for noninvasive airspace evaluation⁽⁹⁻¹¹⁾.

Newer HRCT techniques provide an opportunity for a comprehensive depiction of COPD in term of lung parenchyma and bronchi morphology, as well as lung functionality.

Advantages of MDCT in COPD:

- Early detection of emphysema in asymptomatic chronic smokers (equivalent to COPD stage 0) in time of normal lung function⁽¹²⁾.
- Quantitative evaluation and topographic disposition of emphysema^(12,13,15).
- Characterization of phenotypes of emphysema (centrolobular, panacinar, paraseptal emphysema, localized bubbles) and COPD⁽¹²⁾.
- Significant correlation between MDCT issues and clinical parameters: age, smoking history, St. George's Questionnaire, BMI, spirometry, CPR⁽¹⁶⁾.
- Differential diagnosis of emphysema with other diseases that produce shortness of breath or cough (pneumothorax, bronchiolitis, interstitial lung disease, bronchiectasis)⁽⁸⁾.
- Noninvasive quantitative evaluation of airway dimensions (bronchi and bronchioles, small air spaces) and virtual bronchoscopy^(14,15,17).
- Functional assessment of pulmonary reserve before thoracic surgery (including lung transplantation) and before lung volume reduction techniques (by surgery or by unidirectional valves insertion)⁽¹²⁾.
- 3D reconstruction of the pulmonary vessels and evaluation of different pathologies: shunts, malformations, fistulas, tumors⁽⁸⁾.
- Monitoring of progression of the disease under therapy.

Emphysema detection and characterization

In radiological terms, emphysema consists of parenchymal areas with low attenuation without definable walls. The attenuation coefficient of emphysematous lung usually decreases to a value below minus 950 HU⁽¹⁶⁾. On expiratory CT, air trapping may be quantified by evaluating the percentage of lung volume less than a given threshold (e.g. -856 HU) comparing lung volumes and attenuation between expiration and inspiration.

For emphysema extension, MDCT elaborates a "voxels density mask model" = quantitative analysis of the region with abnormally low attenuation (threshold -950 UH) and calculating the emphysema score (ES)⁽¹⁴⁾. An overall "lung density map" will be created that offers a global picture of the affected lung. MDCT-derived ES seems to be the best predictor of all-cause mortality in a cohort of stable COPD outpatients along with age^(4,9).

In addition, MDCT may highlight several parameters to assess emphysema⁽¹²⁾:

- The thoracic cross-sectional area (measurement of the thoracic cage hyperinflation).
- The sterno-aortic distance at the carineal level (increased in hyperinflation).
- The "saber-sheath trachea configuration" (static modeling of the trachea by coronal narrowing and sagittal widening of the thoracic cage in emphysema).

MDCT is able to indicate also the emphysema distribution. This parameter may be a predictor of mortality (large emphysema in the upper areas associates an increased survival in COPD patients compared to basal localization)⁽¹³⁾.

Different phenotypes of emphysema and of COPD can be differentiated by MDCT with a high degree of sensitivity and specificity^(18,19):

- Early centrilobular emphysema (related to smoking and exposure to gases) is characterized by round low-attenuation in the central area of the secondary pulmonary nodule around the lobular artery⁽²⁰⁾. The secondary pulmonary lobules are not destroyed. As emphysema progresses, the hypertransparent areas become confluent (Figure 1).
- Panlobular emphysema commonly involves the lung bases. It affects the entire secondary pulmonary lobule. Panlobular emphysema typically occurs as a result of α_1 antiprotease deficiency, but may also be determined by chronic smoking in the advanced stage of common COPD. Genetic evaluation of emphysema is useful to identify specific groups of patients who may benefit from specific enzymatic treatment. MDCT is much more sensitive for progression evolution and response to specific therapy than conventional CT or RFTs^(21, 22) (Figure 2).
- Paraseptal emphysema is defined as subpleural, and subfissural gas collection located in the periphery of the secondary pulmonary lobules. It is considered a panlobular type and a precursor of bullae (Figure 3).
- Pericatricial emphysema is found near the scars and is accompanied by parenchymal and bronchial distortion.
- Association of bronchiolitis or bronchiectasis to emphysema includes a poor prognosis, an increased risk for exacerbation, but a better response to inhaled corticoids and bronchodilators^(23, 24) (Figure 4).
- Morphological characterization of emphysema (centri-/ panlobular/ extralobular emphysema) by MDCT correlates with histological analysis⁽⁷⁾.

Imaging of the airways and pulmonary vessels

HRCT/MDCT may characterize both large and small airways by constructing a 3D model of the airways. It can visualize the external and internal diameters of bronchi, the airway wall thickness and the inner design – “virtual bronchoscopy”.

Measurement of airway parameters correlates with the severity of airflow obstruction and with history of COPD exacerbation. Gas trapping was associated with

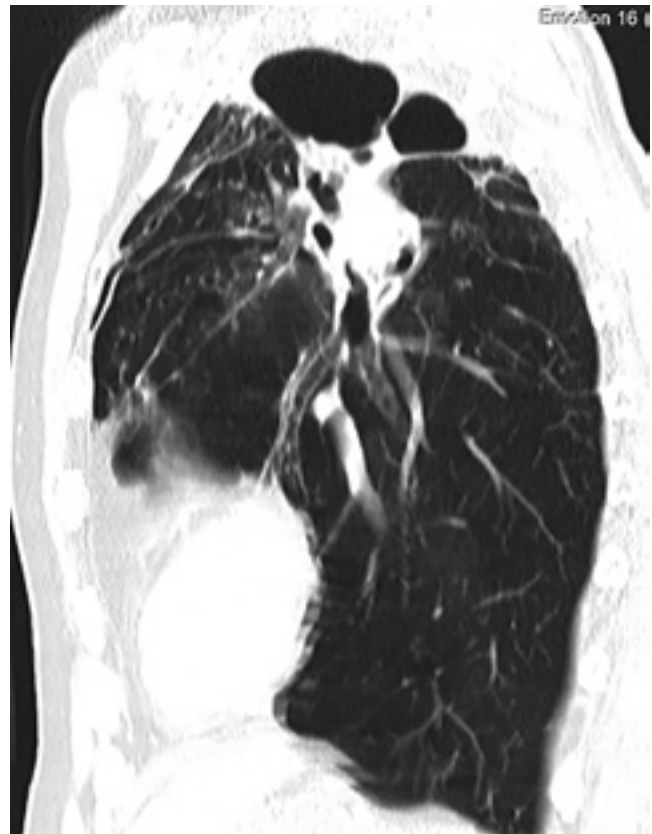

Figure 1. Thoracic CT scan (sagittal section). Diffuse emphysema, multiple apical bullae; bronchiectasis

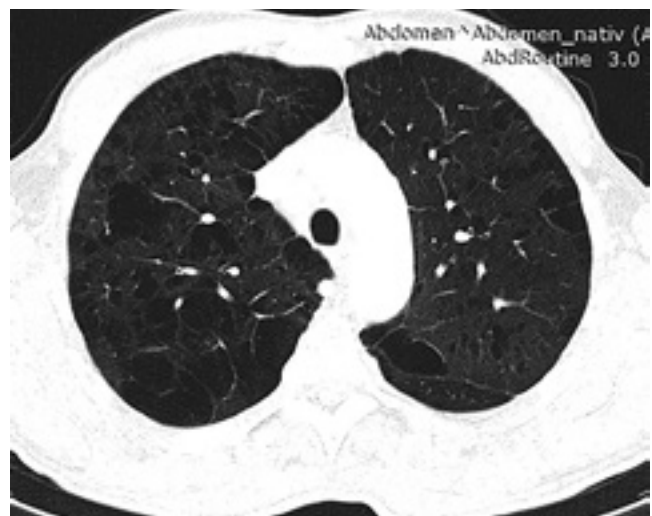
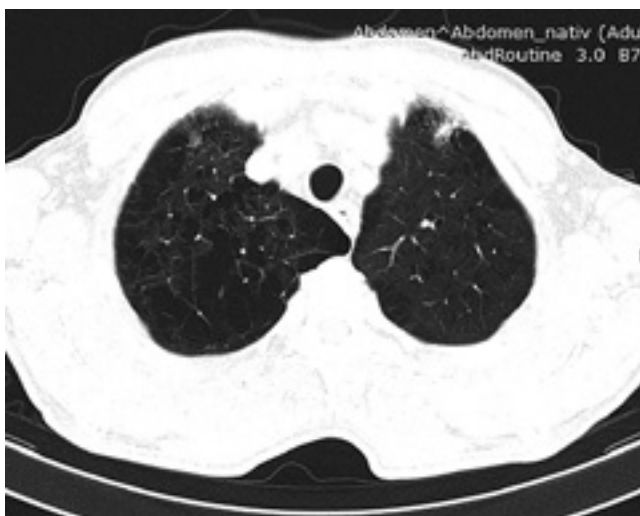
Figure 2. Thoracic CT scan (axial sections): paraseptal emphysema, “mosaic” images of emphysema (with normal and decreased attenuation), panlobular emphysema in right upper lobe (posterior).

smaller airway lumen diameters less than 2 mm, greater dyspnea and chronic bronchitis⁽¹⁵⁾.

The obliteration of the small bronchioles determines patchy high-density areas (under-ventilated areas) of the parenchyma which alternate with low attenuation areas (with air trapping and poor perfusion). It will result a “mosaic attenuation pattern” with a lack of homogeneity of the lung density strongly specific for COPD especially on the end-expiratory scans⁽¹²⁾. Mosaic perfusion pattern has a good correlation with a lower FEV₁ and FEV₁/FVC values⁽¹³⁾.

In the same time, MDCT may accurately characterize the disorders of the large bronchi or trachea (malacia, dilation, stenosis or diverticula, fistulae, tumors)⁽²⁵⁾ (Figure 5). The precise location of the obliterated bronchi that determine the retrostenotic air trapping is important for the lung reduction intervention (by sur-

gery or valves insertion).

Pulmonary vessels can also be characterized by MDCT using several parameters:

- The diameter of the pulmonary artery trunk.
- The diameters of the main pulmonary arteries.
- Wall arteries thickening.
- Vascular distortion (increased angles of arterial branches separation)⁽²⁰⁾.
- Evaluation of “vascular attenuation” (thinning of pulmonary vessels and reduction in their number)⁽¹²⁾. Low “density” of the vascular images occurs in advanced emphysema^(6,11,12).

MDCT/HRCT has shown several benefits for a comprehensive morphological and functional characterization of COPD. It stands as a noninvasive method with multiple valences for an early valuable diagnostic which may indicate a targeted therapy of the disease.

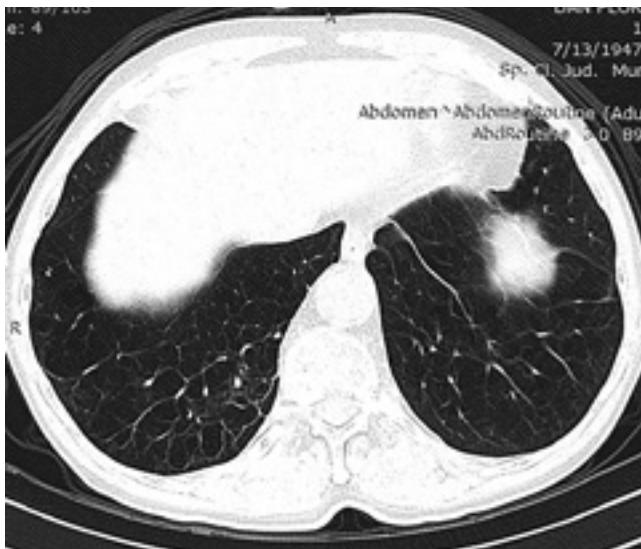

Figure 3. Thoracic CT scan (axial section). Panlobular basal emphysema (CT density - 1024 UH)

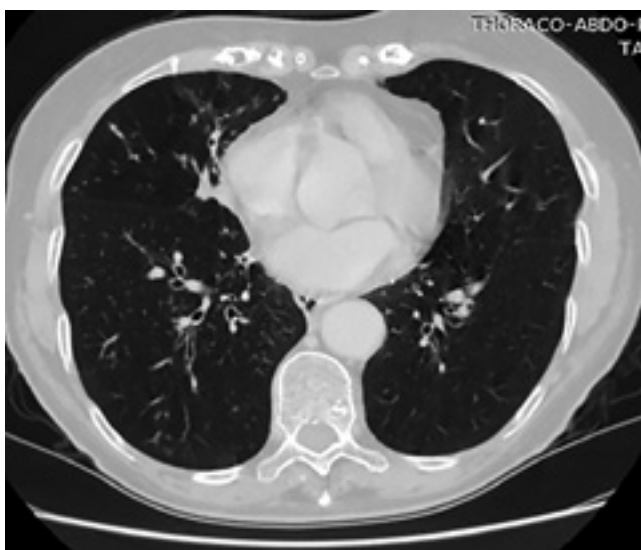
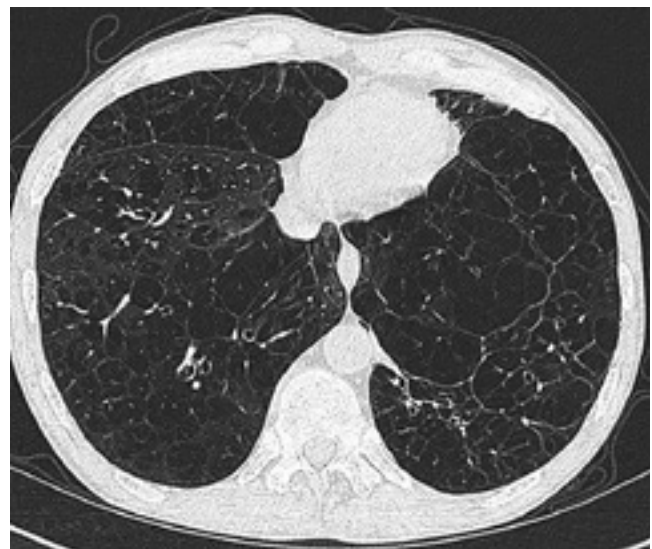
Figure 4. Thoracic CT scan (axial section). Diffuse emphysema. Bronchiectasis and bronchiolitis fenotype (image “tree-in-bud” right lower lobe, posterior)

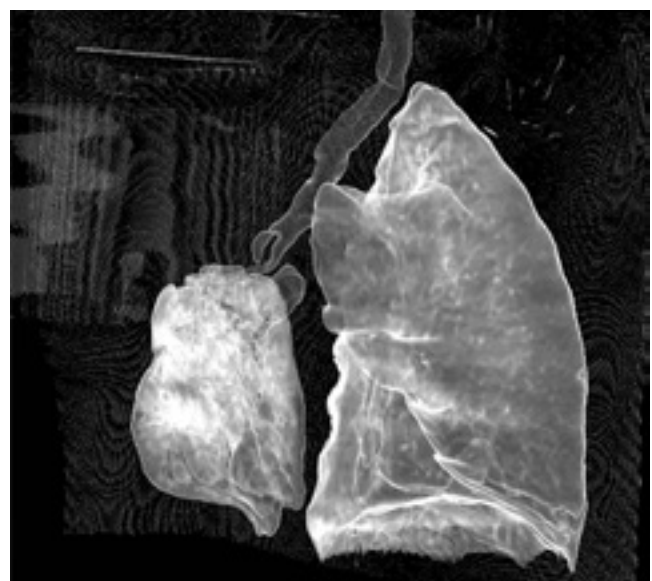


Figure 5. HRCT (3D Reconstruction). Lung bilobar right hypoplasia. Left mediastinal lung hernia.

Further studies are needed on the use of algorithms for precise quantification of changes in different lung structures in emphysema. The risk of irradiation remains the most important disadvantage of the technique which restricts indications for repeated usage of the HRCT. The clinical benefit of MDCT is higher than the risk of radiation. Despite this fact, reduction and optimisation of radiation are strongly recommended in accordance with the ALARA

principle. The dose cannot be higher than the standard dose of 10-20% recommended by scanner vendors⁽²⁶⁾.

Morphologic and quantitative assessment of the lung parenchyma and airways in practice may be obtained at a radiation exposure value of 300-350 mGy×cm. This leads to an effective dose of 5-6 mSv. The COPD patients are usually more than 40 years old, this allowing repeated follow-up CT studies, that might be acceptable⁽²⁷⁾. ■

References

1. Global Initiative for Chronic Obstructive Lung Disease (GOLD) 2016. www.goldcopd.org.
2. Grydeland TB, Dirksen A, Coxson HO et al. Quantitative computed tomography measures of emphysema and airway wall thickness are related to respiratory symptoms. *Am J Respir Crit Care Med*. 2010 Feb 15; 181(4):353-9.
3. Lynch DA, Austin JH, Hogg JC, et al. CT-Definable Subtypes of Chronic Obstructive Pulmonary Disease: A Statement of the Fleischner Society. *Radiology* 2015; 277:192.
4. Afroditi K, Boutou, Arjun Nair, Dariush Douraghi-Zadeh et al. A Combined Pulmonary Function and Emphysema Score Prognostic Index for Staging in COPD Disease Javier J. Zulueta, Editor PLoS One. 2014; 9(10).
5. Dirksen A, Piitulainen E, Parr DG, Deng C, Wencker M et al. Exploring the role of CT densitometry: a randomised study of augmentation therapy in alpha1-antitrypsin deficiency. *Eur Respir J*. (2009) Jun; 33(6):1345-53.
6. Jimborean G, Ianosi ES, Togănel C, Comes A, Arghir O. Radiografia toracică. Tomografia computerizată în Pneumologie. Examen clinic. Explorări paraclinice, Ed. University Press, Târgu-Mureş (2008) 38-73.
7. Coxson HO, Mayo J, Lam S, Santyr G, Parraga G, Sin DD. New and Current Clinical Imaging Techniques to Study COPD, *Am J of Resp Crit Care Med* 2009, Vol 180, 588-597.
8. Kurashima K, Takayanagi N, Sato N, et al. HRCT and bronchial reversibility test for diagnosing COPD. *Respirology* 2005; 10: 316-22.
9. Haruna A, Muro S, Nakano Y, Ohara T, Hoshino Y, Ogawa E, et al. CT scan findings of emphysema predict mortality in COPD. *Chest* (2010); 138(3):635-40.
10. Choromanska A, Macura K. Role of computed tomography in quantitative assessment of emphysema. *Pol J Radiol*. 2012; 77(1):28-36.
11. Coxson HO, Leipsic J, Parraga G, Sin DD. Using Pulmonary Imaging to Move COPD beyond FEV. *Am J Respir Crit Care Med*, 2014, Vol 190 (2), 135-144.
12. Gupta PP, Yadav R, Verma M, Gupta KB, Agarwal D. High resolution computed tomography features in patients with COPD. *Singapore Med J* 2009, 50: 193-200.
13. Silva CI, Marchiori E, Souza AS, Júnior, Müller NL, Comissão de Imagem da Sociedade Brasileira de Pneumologia e Tisiologia Illustrated Brazilian consensus of terms and fundamental patterns in chest CT scans. *J Bras Pneumol*. 2010; 36(1):99-123.
14. Chabat F, Wells AU. Quantification of emphysema: A composite physiologic index derived from CT estimation of disease extent. *Eur Radiol* 2007, 17: 911-8.
15. Smith BM, Hoffman EA, Basner RC, Kawut SM, Kalhan R, Barr RG. Not all measures of hyperinflation are created equal: lung structure and clinical correlates of gas trapping and hyperexpansion in COPD: the Multi-Ethnic Study of Atherosclerosis (MESA) COPD Study. *Chest*. 2014 Jun; 145(6):1305-15.
16. Wang JS, Cherng JM, Perng DS, Lee HS, Wang S. High-resolution computed tomography in assessment of patients with emphysema. *Respir Care*. 2013 Apr; 58(4):614-22.
17. Hansell DM. Small airways diseases: detection and insights with computed tomography. *Eur Respir J* 2001, 17: 1294-1313.
18. Bergin CJ, Müller NL, Miller RR. CT in the qualitative assessment of emphysema. *J Thorac Imaging* 1986; 1:94.
19. Bonelli FS, Hartman TE, Swensen SJ, Sherrick A. Accuracy of high-resolution CT in diagnosing lung diseases. *AJR Am J Roentgenol* 1998; 170:1507.
20. Mostafa M. Role of chest radiography, spirometry, and high resolution computed tomography in the early diagnosis of emphysema. *Egypt J Radiol Nucl Med*. 2010, 41(4): 509-515.
21. Parr DG, Sevenoaks M, Deng C, Stoel BC, Stockley RA. Detection of emphysema progression in alpha 1-antitrypsin deficiency using CT densitometry. *Respir Res*. (2008) Feb 13; 9:21.
22. Dirksen A, Piitulainen E, Parr DG, Deng C, Wencker M et al. Exploring the role of CT densitometry: a randomized study of augmentation therapy in alpha1-antitrypsin deficiency. *Eur Respir J*. (2009) Jun; 33(6):1345-53.
23. Hogg JC State of the art. Bronchiolitis in COPD, *Proc Am Thorac Soc* (2006) Aug; 3(6):489-93.
24. Nakano Y, Wong JC, de Jong PA et al. The prediction of small airway dimensions using computed tomography. *Am J Respir Crit Care Med*. (2005), Jan 15; 171(2):142-6.
25. Sverzellati N, Rastelli A, Chetta A et al. Airway malacia in chronic obstructive pulmonary disease: prevalence, morphology and relationship with emphysema, bronchiectasis and bronchial wall thickening. *Chest. European Radiology*. July 2009, Vol 19 (7), 1669-1678.
26. Piere Alain Gevenois, Denis Track. Dose reduction and optimization in Computed Tomography of the Chest. *Radiation Dose from Multidetector CT*. Second Edition, 2012, 307-317.
27. Pierre-Yves Brillet, Catalin I Fetita, Amaury Saragaglia et al. Investigation of airways using MDCT for visual and quantitative assessment in COPD patients. *Int J Chron Obstruct Pulmon Dis*. 2008 Mar; 3(1): 97-107.

Înscrierea ca membru al Societății Române de Pneumologie

Începând cu anul 2017 înscrierea ca membru al Societății Române de Pneumologie se face **exclusiv online**, prin completarea formularului de înscriere disponibil la pagina de internet a societății, **www.srp.ro**.

Taxa de înscriere	Până la 1 martie 2017	După 1 martie 2017
Membru titular SRP*	240 lei	270 lei
Membru titular pensionar, medic rezident SRP*	120 lei	135 lei
Membru asociat SRP	48 lei	54 lei
Taxe adiționale		
Membru al World Association for Bronchology and Interventional Pulmonology (WABIP) - 5 dolari	25 lei	

*Taxa include cotizația pe anul 2017, abonamentul la revista „Pneumologia“ (4 numere) și taxa de membru ERS.

Membrilor SRP le sunt acordate toate drepturile și privilegiile specificate în Constituția și Statutul ERS, în ultimele versiuni aprobate. Pentru abonamentul anual la revista „Pneumologia“ membrilor Colegiului Medicilor din România li se acordă 10 credite de educație medicală continuă (EMC).

Membri titulari pot fi medici, biologi, farmaciști, chimiști, fizicieni și persoane cu alte profesii înrudite care activează în domeniul bolilor respiratorii (asistență medicală, cercetare, învățământ).

Membri asociați pot fi asistenți medicali, kinetoterapeuți, tehnicieni care activează în domeniul bolilor respiratorii (cercetare, învățământ, îngrijirea pacienților).