

Massive hemoptysis due to intercostal artery aneurysm in pulmonary tuberculosis

Hemoptizie masivă secundară a aneurismului de arteră intercostală la pacient cu tuberculoză pulmonară

Diego Hernández-Velásquez¹,
Roberto Monreal-Robles²,
Diego Ruiz-Sánchez³,
Guillermo Delgado-García²

¹ Service of Pulmonology and Intensive Care Unit,

² Department of Internal Medicine,

³ Department of Radiology, University Hospital, Autonomous University of Nuevo León.

Corresponding author:

Roberto Monreal-Robles, M.D.
Department of Internal Medicine,
University Hospital, Autonomous
University of Nuevo León,
Madero y Gonzalitos s/n, Col. Mitrás
Centro, C. P. 64460, Monterrey,
E-mail: roberto.monrealrb@uanl.edu.mx

Abstract

Massive hemoptysis is a life-threatening complication of pulmonary tuberculosis. In the presence of pulmonary tuberculosis, massive hemoptysis can result from a number of different causes, with an artery aneurysm being rarely reported. Here we present a case of recurrent massive hemoptysis in a 28-year-old man suffering from active pulmonary tuberculosis due to an aneurysmatic lesion of the second intercostal artery. In patients presented with recurrent massive hemoptysis the non-bronchial systemic arterial blood supply should be assessed.

Keywords: Intercostal artery aneurysm; massive hemoptysis; pulmonary tuberculosis; angiography

Rezumat

Hemoptizia masivă este o complicație a tuberculozei pulmonare amenințătoare de viață. Hemoptizia din tuberculoza pulmonară poate fi cauzată prin multiple mecanisme, însă rar a fost raportată ca o consecință a aneurismului de arteră. Prezentăm cazul unui pacient de 28 de ani diagnosticat cu tuberculoză pulmonară ce a prezentat hemoptizii masive recurente secundare unui aneurism de arteră intercostală. La pacienții ce prezintă hemoptizii recurente masive, sistemul arterial trebuie evaluat.

Cuvinte-cheie: aneurism de arteră intercostală, hemoptizie masivă, tuberculoză pulmonară, angiografie

Introduction

Massive hemoptysis is defined as the expectoration of more than 500 mL of blood within a 24-hour period⁽¹⁾. Without appropriate treatment, massive hemoptysis has a mortality rate of up to 50%⁽²⁾. Several pulmonary conditions can lead to massive hemoptysis, such as neoplasms, tuberculosis, bronchiectasis, and cystic fibrosis⁽³⁾. In the great majority of cases the bleeding source is a bronchial or other systemic artery. Bleeding into tuberculous cavities is common, but massive hemoptysis is rare and has been described as a result of pulmonary artery aneurysms, when the artery is focally weakened by the inflammatory infiltrate. When massive hemoptysis is present, a timely diagnostic and therapeutic approach must be instituted and individualized in order to achieve a favorable outcome. We report the first case of a young man with pulmonary tuberculosis reactivation who presented massive hemoptysis related to an intercostal artery aneurysm, and then highlight the importance and current role of angiographic diagnostic and therapeutic tools, and the place of pulmonary surgery in these patients.

Case presentation

A 28-year-old male inmate from Northeast Mexico presented to the emergency room with a 12-hour history of massive hemoptysis. He had a history of tobacco, alcohol and

previous use of marihuana and cocaine one year ago. He denied a previous history of surgery or traumatic event. The patient had pulmonary tuberculosis diagnosed 1 year earlier for which he was started on oral antituberculous drugs with poor adherence to treatment. On admission, physical examination revealed a blood pressure of 90/60 mmHg, heart rate of 90 bpm, respiratory rate of 20 per minute and SpO₂ 94% on room air. We found traces of blood in the oral cavity and no neck masses or adenopathy. Diffuse crackles in the left lung were heard. Initial laboratory tests revealed a hematocrit of 36.8%, white blood cell count 10,100 cells/ μ L, and a platelet count of 321,000/ μ L. Liver and renal function tests were normal. Viral markers for HIV, hepatitis B and C were all negative. Coagulation profile was also normal. Chest X-ray and computerized tomography (CT) scan revealed active pulmonary tuberculosis (Fig. 1, Fig. 2).

During his stay in the emergency room, further episodes of hemoptysis were consigned with a consequent decrease in the hematocrit (14.5%). Two units of packed red blood cells were transfused. Selective bronchial angiography was performed, however, no site of bleeding was found. Because of the findings on the lung CT, we performed selective intercostal artery angiography where the culprit vessel was identified (Fig. 3). Because arterial embolization attempt was failed and the patient continued with several episodes of hemoptysis, we

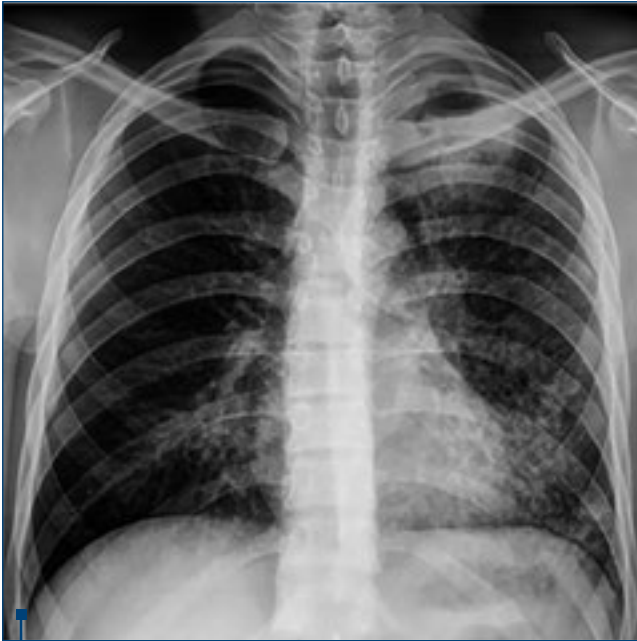

Figure 1. Initial chest x-ray with a diffuse left micronodular lung infiltrate and a left upper lobe cavity

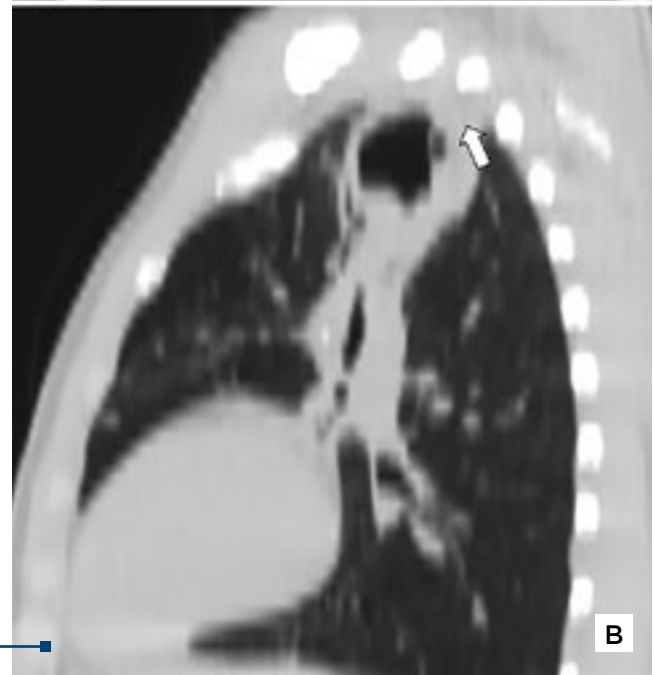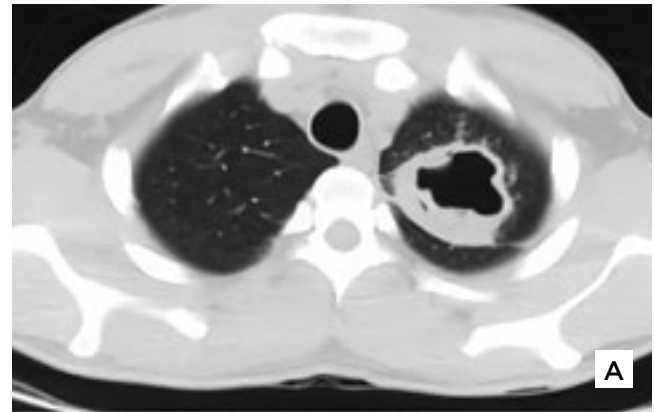


Figure 2. CT scan of the lungs. A, Axial Lung CT demonstrates a thick wall cavity in the left upper lobe containing a fluid level. B, Sagittal reformatted projection demonstrating pulmonary cavity contact with the posterior chest wall at the second intercostal space (white arrow)

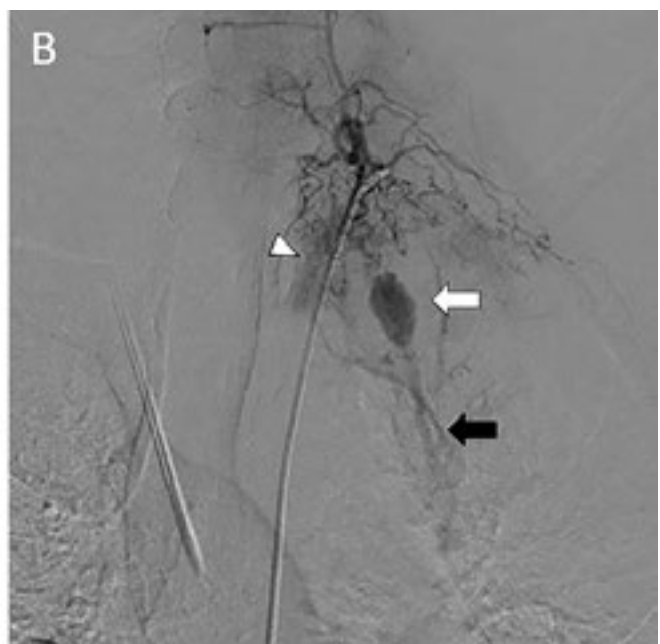
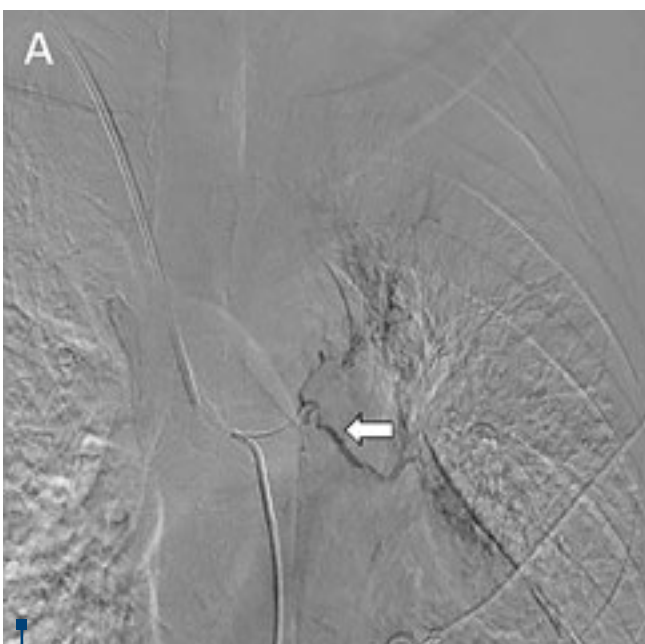

Fig. 3. Digital subtraction angiography images. A, selective left bronchial artery angiography (white arrow) demonstrates no site of bleeding. B, selective intercostal artery angiography shows vessel tortuosity surrounding the pulmonary cavity with abnormal contrast blush in the pulmonary cavity (arrowhead). We observed a saccular aneurysm (white arrow) arising from the second intercostal artery and a systemic artery-to-pulmonary vein shunt (black arrow).

decided to perform thoracotomy and left upper lobectomy. The pathological analysis revealed a chronic granulomatous process with caseous necrosis positive for acid-fast bacilli. The patient was discharged stable on antituberculous drugs and no recurrent hemoptysis was reported.

Discussion

As far as we know, massive hemoptysis due to an intercostal artery aneurysm in active tuberculosis has never been reported. The few reports of massive hemoptysis due to an aneurysmatic lesion in cavitary tuberculosis are due to the involvement of bronchial or pulmonary arteries^(4,5). In fact, hemoptysis due to aneurysms in the context of tuberculosis involving other systemic arteries is rarely reported⁽⁶⁾. Underlying mechanism by which aneurysmatic lesion arises may be the result of artery wall weakening from an adjacent tuberculous cavity as previously described in other non-systemic aneurysmatic lesions⁽⁷⁾. Tunica adventitia and tunica media are replaced by granulation tissue resulting in further weakening and thinning of the arterial wall, producing an aneurysmatic dilatation of the vessel⁽⁷⁾.

Initial recommended step in the management of massive hemoptysis is to localize the site of arterial bleeding in order to perform artery embolization. Emergency surgery is reserved for cases where the above measures are insufficient to control bleeding. Since aneurysmal rupture resulting in massive hemoptysis is potentially fatal, a prompt diagnostic and therapeutic approach must be made. The advent of contrast-enhanced CT angiography has enabled a noninvasive, first-line method of localizing the site of arterial bleeding in the setting of massive hemoptysis⁽⁸⁾. Even though pulmonary or bronchial arteries are the main source of massive hemoptysis, it is recommended to search for bleeding from non-bronchial systemic arterial supply, including the intercostal arteries⁽⁹⁾. Prominence, tortuosity, and contrast blush are typical imaging

findings relevant to culprit non-bronchial systemic vessels, as in this case⁽⁹⁾. The presence of an intercostal aneurysm is rare and is usually associated with type I neurofibromatosis, aortic coarctation, or trauma⁽¹⁰⁾.

Once aneurysmatic lesion is identified by an angiographic study, artery embolization seems to be an option to consider. Emergency arterial embolization and transcatheter occlusion have been reported as a successful strategy and is actually becoming a standard first-line treatment option for the management of unstable patients with acute arterial bleeding from any source, bronchial and nonbronchial systemic arteries^(11,12). This approach has been previously described for the treatment of massive hemoptysis of intercostal arteries⁽¹³⁾ and it has also been demonstrated to be a safe procedure in the setting of cavitary tuberculosis⁽¹¹⁾.

In this case where the therapeutic artery embolization failed in the setting of continuous hemoptysis, we decided to take the patient to surgery and perform left upper lobectomy. Lobectomy has the advantage of providing definitive management of the site of bleeding with a 0% reported recurrence⁽³⁾ in comparison with a recurrence rate of >20% with arterial embolization⁽¹⁴⁾. Even though common postoperative complications in lobectomy exist⁽⁹⁾, a lower postoperative mortality (2.2%) has been reported in delayed elective surgery⁽¹⁵⁾.

Because of diagnostic catheter angiography's potential risk of aneurysm rupture and the high rate of bleeding recurrence in pulmonary tuberculosis, definitive treatment for massive hemoptysis by surgical resection must be considered in the correct scenario.

In conclusion, assessment of non-bronchial systemic arterial blood supply should be considered in patients with recurrent massive hemoptysis. Surgical resection in the correctly selected patient continues to be definitive treatment for massive hemoptysis with an acceptable rate of related procedure morbidity and mortality. ■

References

- Hirshberg B, Biran I, Glazer M, et al. Hemoptysis: etiology, evaluation, and outcome in a tertiary referral hospital. *Chest*. 1997;112:440-4.
- Conlan AA, Hurwitz SS, Krige L, et al. Massive hemoptysis. Review of 123 cases. *The Journal of thoracic and cardiovascular surgery*. 1983;85:120-4.
- Knott-Craig CJ, Oosthuizen JG, Rossouw G, et al. Management and prognosis of massive hemoptysis. Recent experience with 120 patients. *The Journal of thoracic and cardiovascular surgery*. 1993;105:394-7.
- Iriki T, Morinoa E, Takasakia J, et al. Contrast-enhanced chest computed tomography leads to early diagnosis and prompt treatment of unruptured Rasmussen's aneurysm. *AJRS*. 2012;1:439-44.
- Karmakar S, Nath A, Neyaz Z, et al. Bronchial Artery Aneurysm due to Pulmonary Tuberculosis: Detection with Multidetector Computed Tomographic Angiography. *Journal of clinical imaging science*. 2011;1:26.
- Singhal M, Giragani S, Lal A, et al. An unusual cause of hemoptysis: costocervical trunk pseudoaneurysm. *Emergency radiology*. 2011;18:53-5.
- Kim HY, Song KS, Goo JM, et al. Thoracic sequelae and complications of tuberculosis. *Radiographics : a review publication of the Radiological Society of North America, Inc*. 2001;21:839-58; discussion 59-60.
- Noe GD, Jaffe SM, Molan MP. CT and CT angiography in massive haemoptysis with emphasis on pre-embolization assessment. *Clinical radiology*. 2011;66:869-75.
- Remy J, Voisin C, Ribet M, et al. Treatment, by embolization, of severe or repeated hemoptysis associated with systemic hypervascularization. *La Nouvelle presse medicale*. 1973;2:2060.
- Kawahito K, Adachi H. Solitary intercostal artery aneurysm. *Asian cardiovascular & thoracic annals*. 2014;22:879.
- Remy J, Lemaitre L, Lafitte JJ, et al. Massive hemoptysis of pulmonary arterial origin: diagnosis and treatment. *AJR*. 1984;143:963-9.
- Yoon W, Kim JK, Kim YH, et al. Bronchial and nonbronchial systemic artery embolization for life-threatening hemoptysis: a comprehensive review. *Radiographics : a review publication of the Radiological Society of North America, Inc*. 2002;22:1395-409.
- Vujic I, Pyle R, Parker E, et al. Control of massive hemoptysis by embolization of intercostal arteries. *Radiology*. 1980;137:617-20.
- Shao H, Wu J, Wu Q, et al. Bronchial artery embolization for hemoptysis: a retrospective observational study of 344 patients. *Chinese medical journal*. 2015;128:58-62.
- Zhang Y, Chen C, Jiang GN. Surgery of massive hemoptysis in pulmonary tuberculosis: immediate and long-term outcomes. *The Journal of thoracic and cardiovascular surgery*. 2014;148:651-6.