

# Sarcoidosis and Aspergillosis: case presentation

## Sarcoidoză și aspergiloză: prezentare de caz

Bianca Paraschiv<sup>1</sup>,  
Anne-Charlotte  
Sellier<sup>2</sup>,  
Camelia Diaconu<sup>3</sup>,  
R my Bernard<sup>4</sup>

1. "Marius Nasta" Institute of  
Pneumology,  
Bucharest, Romania

2. "Cavale Blanche" Centre  
Hospitalier R gional et  
Universitaire de Brest, France

3. Floreasca Clinical  
Emergency Hospital,  
Bucharest, Romania

4. Laennec Centre Hospitalier  
de Cournouaille,  
Quimper, France

Corresponding author:

Dr. Bianca Paraschiv  
"Marius Nasta" Institute of  
Pneumology  
90 Sos. Vilior, 5th district,  
Bucharest, 050152, Romania  
E-mail: paraschiv.bianca@gmail.com

### Abstract

*Sarcoidosis is a multisystemic inflammatory disease of unknown etiology, characterized by noncaseous epithelioid cell granulomas. The evolution of the disease may be complicated by opportunistic infections such as aspergillosis, that usually appears in type IV sarcoidosis. We present the case of a 74 year-old women with a history of sarcoidosis for over 7 years, who presented for hemoptysis. She was diagnosed with pulmonary cavitary aspergillosis and treatment with Itraconazole was initiated. The patient was monitored every two months. At the one year follow up, the patient was asymptomatic, with a good treatment tolerance and no decline in lung function, despite the pulmonary fibrosis. The sputum exams continued to be positive for Aspergillus, the HRCT-scan described a chronic pulmonary aspergillosis. The antifungal treatment was continued, under careful monitoring. The patient remained asymptomatic with no further decline in lung volumes. The particularity of the case consists in the lack of symptoms, despite pulmonary fibrosis, and the therapeutic challenges of chronic pulmonary aspergillosis.*

**Keywords:** sarcoidosis, pulmonary aspergillosis, fibrosis

### Rezumat

*Sarcoidoza este o boal  inflamatorie sistemică de etiologie neprecizată caracterizată prin formarea granuloamelor epiteloide noncaseificate. Evoluția bolii este grevată de apariția infecțiilor oportuniste, ca de exemplu Aspergiloza, ce este descrisă cu precădere în tipul IV de sarcoidoză. Prezentăm cazul unei paciente de 74 de ani, diagnosticată cu sarcoidoză în urmă cu 7 ani, care se prezintă pentru hemoptizii. Pacienta a fost diagnosticată cu aspergiloză pulmonară cavitară și s-a inițiat tratamentul cu Itraconazol, fiind monitorizată la fiecare 2 luni. La controlul efectuat după un an, pacienta a fost asimptomatică, funcția respiratorie fiind conservată, deși s-a înregistrat o progresie radiologică, cu o bună toleranță terapeutică. Examenele de spută au continuat să fie intens pozitive pentru Aspergillus, iar aspectul tomografic a fost în favoarea unei aspergiloze cronice cavitare. Deoarece nu s-au repetat episoadele de hemoptizie sub tratament antifungic, s-a decis continuarea acestuia sub supraveghere periodică. Particularitatea cazului rezidă în lipsa tabloului clinic în stadiul de fibroză pulmonară și dificultatea terapeutică a aspergilozei pulmonare cronice cavitare asociate cu sarcoidoza, la o pacientă fără cauze identificate de imunodepresie.*

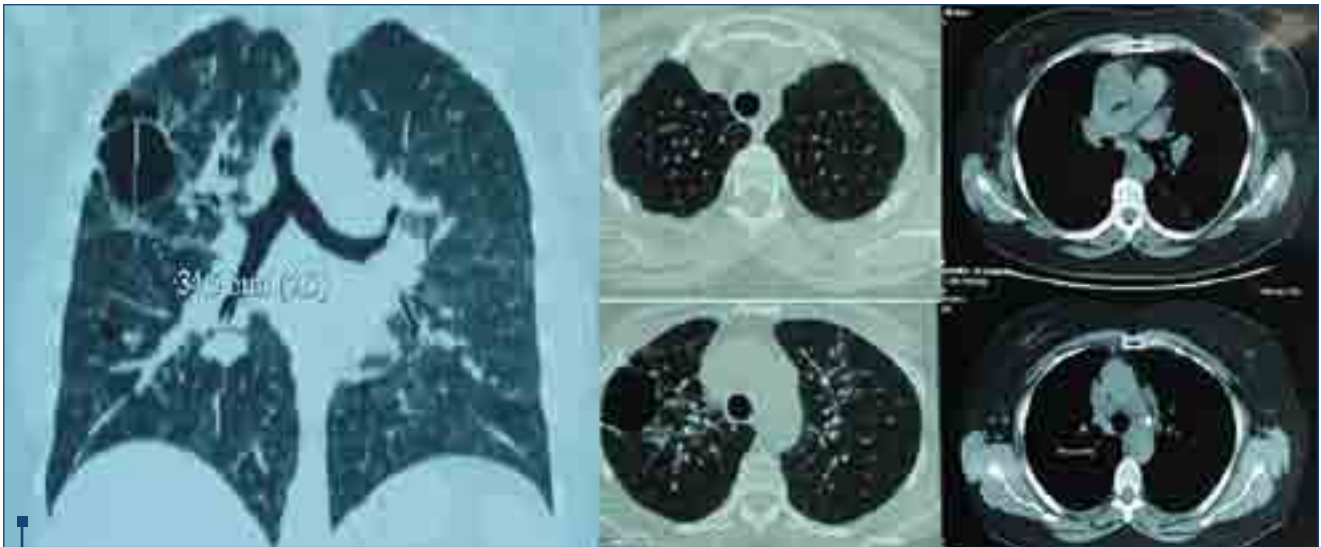
**Cuvinte-cheie:** sarcoidoză, aspergiloză pulmonară

## Introduction

Sarcoidosis is a systemic inflammatory disease generated by an inappropriate immune response. The pulmonary involvement is present in more than 90% of cases, with the overall mortality reported at 1-5%<sup>1</sup>. The disease has a higher prevalence in adults under the age of 40<sup>1</sup>. Sarcoidosis is diagnosed incidentally on chest X-ray prior to the development of symptoms. The etiology of sarcoidosis remains unknown, although many speculations have been made: infections (Mycobacterium, Mycoplasma, viruses), aluminium, pine tree pollen. The diagnosis is suggested by clinical symptoms and signs, radiological aspects and exclusion of other diseases with similar features. The identification of noncaseous granuloma represents the histological confirmation, obtained by performing a biopsy of the most accessible lesion. Biopsy confirmation is not required in cases with clinical and radiological aspects highly suggestive for sarcoidosis. Once the positive diagnosis has been made, the extent and severity of the disease must be assessed in order to decide if treatment is required. The treatment initiation, the appropriate therapy and the treatment length remain controversial. Because sarcoidosis has a highly variable evolution and prognosis, patients should be frequently monitored. There is no consensus regarding specific tests or optimal frequency of monitoring of

disease progression in sarcoidosis. Several studies of pulmonary sarcoidosis suggest clinical and radiological surveillance every 6 months in patients with radiological stage I and every 3 months in other stages<sup>1</sup>. Also patients should be monitored for at least 3 years after discontinuation of treatment<sup>1</sup>. This constant surveillance is necessary for possible complications that may appear due to disease progression or treatment. Opportunistic infections usually develop in fibrocystic lungs seen in type IV sarcoidosis: mycobacteria, cryptococcosis, nocardiosis, histoplasmosis and aspergillosis<sup>2</sup>.

Aspergillus is a ubiquitous fungus. Pulmonary infections with Aspergillus may have symptoms as a result of interactions between the fungus and the host immune system. Allergic broncho-pulmonary aspergillosis is a hypersensitivity reaction to fungus antigens, frequently seen in patients with asthma and cystic fibrosis. Aspergilloma is the most common form of pulmonary involvement and it consists of masses of fungus and inflammatory cells, formed in a preexisting lung cavity. Chronic pulmonary aspergillosis represents a group of diseases: aspergilloma, chronic cavitary pulmonary aspergillosis, chronic fibrosing pulmonary aspergillosis, chronic necrotising aspergillosis. Aspergilloma is a fungus ball formed in a preexisting pulmonary cavity colonised with Aspergillus. Chronic cavitary pulmonary



**Figure 1.** CT scan in 2007: bilateral interstitial syndrome with enlarged mediastinal lymph nodes up to 22 cm, cavity in the right upper lobe

aspergillosis defines formation and expansion of pulmonary cavities in immunocompetent patients over several months. Chronic fibrosing pulmonary aspergillosis represents a late stage of the previous disease with a marked extension and fibrosis. Chronic necrotising aspergillosis is characterised by local invasion of lung tissue, where a pre-existing cavity is not needed. As a sign of disease progression, a cavity with a fungal ball may develop, secondary to tissue destruction. Invasive pulmonary aspergillosis is the most severe form of *Aspergillus* infection and it appears predominantly in immunocompromised patients<sup>3</sup>.

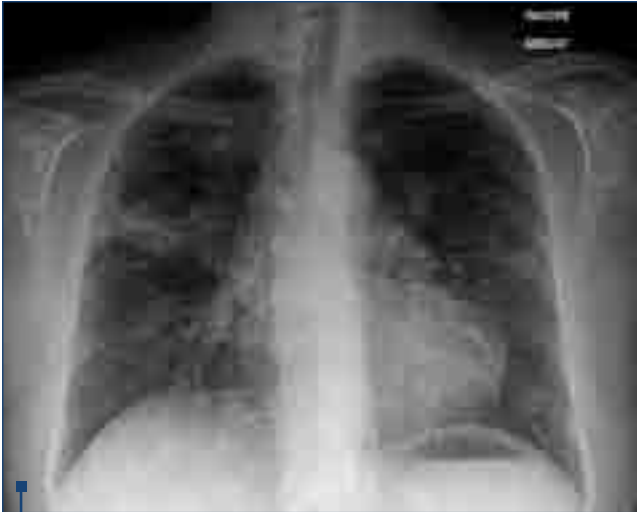Chronic cavitary pulmonary aspergillosis (CPA) has been associated with tuberculosis, chronic obstructive pulmonary disease, pneumoconiosis and sarcoidosis<sup>4</sup>. Its prevalence has been reported between 3-12% in patients with sarcoidosis<sup>5</sup>. The association between sarcoidosis and CPA implies a poor prognosis due to limited therapeutic options. Treatment options include antifungal medication, such as Itraconazole 200-400mg per day, for at least 6 to 8 months. Recurrence of aspergilloma may appear after treatment discontinuation. Surgical resection remains the last option due to possible complications and high mortality<sup>6</sup>.

### Case presentation

We present the case of a 74 year-old Caucasian woman, who presented in February 2014 to our hospital for a history of progressive dyspnea, fever and haemoptysis. Previous medical history included a stage II sarcoidosis diagnosed in 2007, arterial hypertension and a colecystectomy in 2013. She had no history of smoking or exposure to antigens. The patient presented in 2007 with dry cough and joint pain, the rest of clinical exam was normal. Pulmonary function tests were normal: FEV1/FVC ratio 85%, FVC 1.96L (93% predicted), FEV1 1.67L (102% predicted). There are no available results

for diffusion capacity (DLCO) or the 6 minute walk test (6MWT). The tuberculin skin test was negative. The serologic testing for HIV infection was also negative. Laboratory tests were in normal range. All the antibodies for diffuse interstitial pneumonia were negative. The HRCT scan identified bilateral interstitial syndrome with enlarged mediastinal lymph nodes up to 22 cm and the presence of a cavity in the right upper lobe (Figure 1). The presence of the cavitation raised several hypotheses: cavitating malignancy, infection such as fungal, tuberculosis, nocardiosis, actinomycosis or pneumonia, pulmonary infarct, sarcoidosis, X histiocytosis. The patient had no weight loss, no clinical signs of infection, negative tuberculin skin test and no inflammatory syndrome. The patient refused fibroscopy at that moment. Given the clinical presentation (mild respiratory symptoms, arthritis) and paraclinical features (bilateral interstitial syndrome with normal pulmonary function, normal laboratory tests) sarcoidosis seemed the most likely diagnosis. A histological confirmation could not be obtained due to the patient's refusal. In the absence of severe organ involvement no treatment was initiated. A careful monitoring was considered suitable given the presence of the cavitation and the lack of histological confirmation.

At one year follow-up, the patient had a normal clinical exam, with no joint pain or dyspnea, with no alteration in lung volumes and an unchanged CT scan result. The patient once more refused the biopsy. Given the clinical and radiological stability without treatment, sarcoidosis seemed the right diagnosis. The patient was lost to follow up until 2011, when she presented with persistent dry cough; no other organ involvement was diagnosed. Results of lung function tests showed normal pulmonary volumes with a mild decrease in DLCO. The chest X-ray aspect was similar to the one in 2007. Inhaled corticoids were initiated as an alternative to



**Figure 2.** Chest X-ray in February 2014. Bilateral alveolar syndrome with right superior lobe abscess

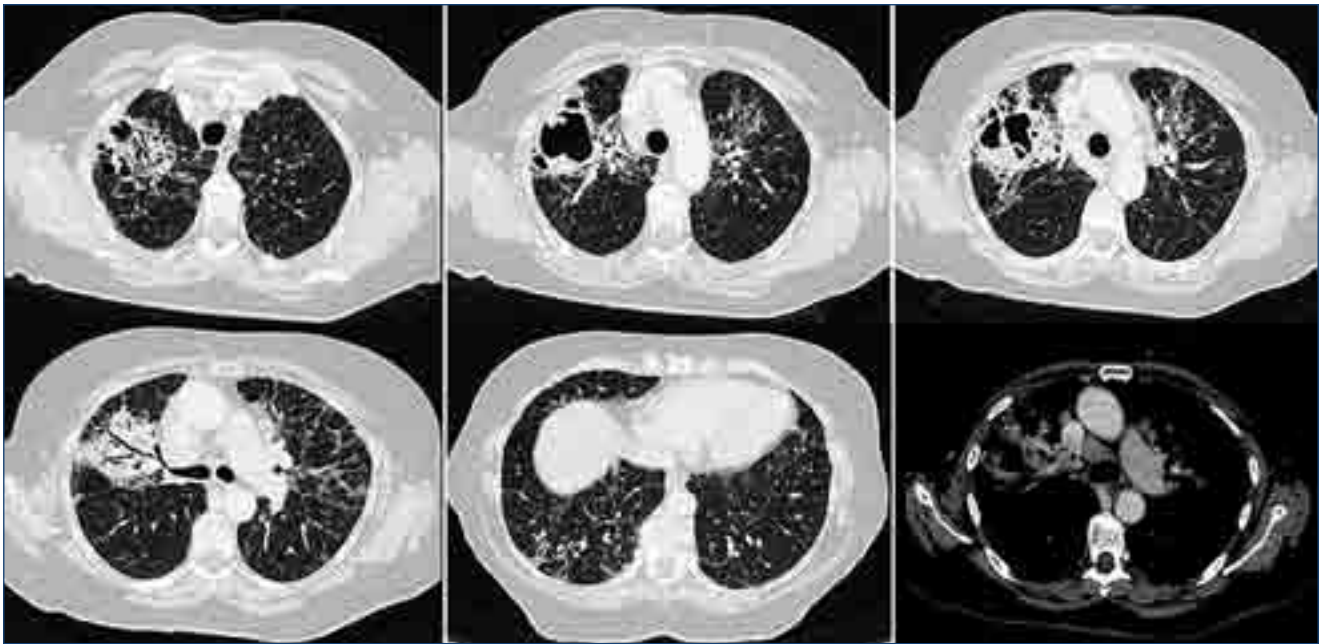
oral therapy due to persistent cough associated with stage II of the disease and the presence of the cavitation with potential to develop a fungus. Under inhaled therapy clinical amelioration was obtained. In 2012, the patient had fatigue, without dyspnea, with a saturation of 96% while breathing ambient air and PaO<sub>2</sub> 80mmHg. The laboratory tests, including calcium level and liver enzymes, were normal. Pulmonary function tests showed normal pulmonary volumes and a moderate reduction in DLCO: FEV<sub>1</sub>/FVC ratio of 85%, FVC 1.71L (89% predicted), FEV<sub>1</sub> 1.54L (94% predicted), DLCO 2.49 (60%). The angiotensin-converting enzyme concentration was 42 UECA. The HRCT scan showed a slight progression compared to 2007. The 6 minute walk test found a mild desaturation to 90% from the initial 96%. Due to lack of symptoms and a good arterial oxygen concentration, only monitoring was decided, without starting oral corticosteroids. The treatment by inhaled corticosteroids was continued by the patient against medical advice.

In December 2013 the patient presented with persistent cough, dyspnea and fever (38–39°C), despite antibiotic treatment with beta lactamines and fluoroquinolones. Two days prior to hospital admission the patient presented haemoptysis. Physical examination found an overweight patient (BMI 32kg/m<sup>2</sup>), without rest dyspnea and SaO<sub>2</sub> of 95% while breathing ambient air. No peripheral lymphadenopathy, arthritis or signs of cardiac failure were found. Laboratory tests showed a mild leucocytosis (10.000/mm<sup>3</sup>) with neutrophilia, and increased CRP (27 mg/L); the angiotensin-converting enzyme (ACE) concentration was 15 UECA. The tuberculin skin test remained negative. The sputum exam was negative for acid-fast bacilli, but identified 20 colonies of *Aspergillus*. The chest X-ray showed an abscess in the right superior lobe (Figure 2). The HRCT scan showed a mass in the right upper lobe, bronchiectasis in the middle right lobe and fibrosis in the upper lobes; the adenopathies were stable in comparison to the scan from 2012

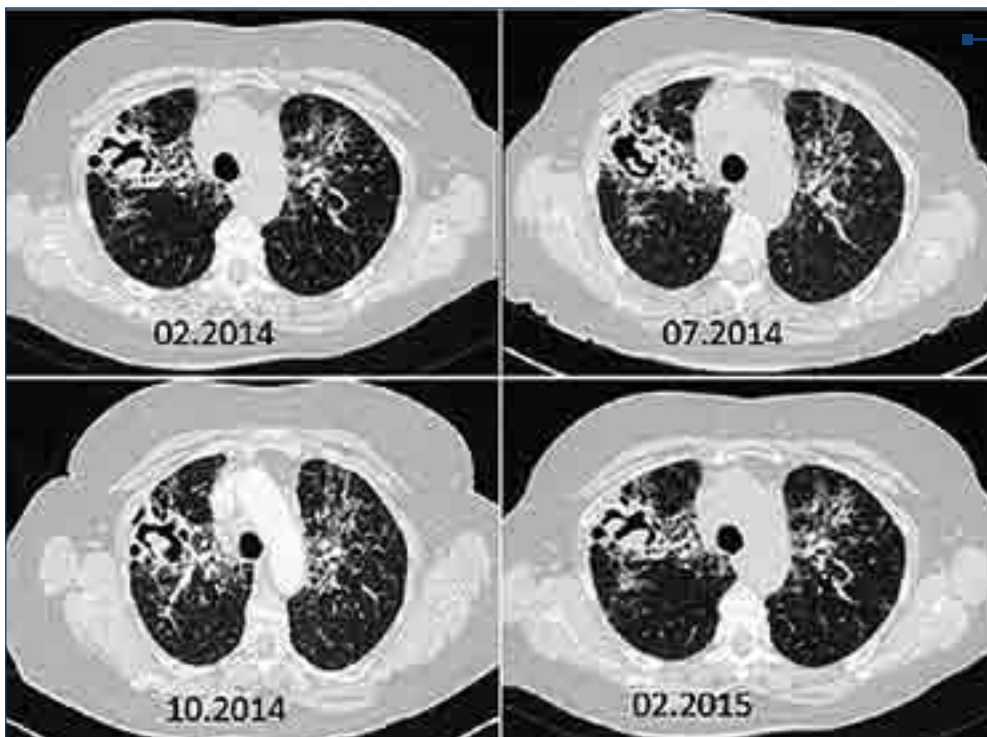
(Figure 3). Given the patient's history, a biopsy was proposed. The bronchoscopy revealed nonspecific global inflammation. Bronchoalveolar lavage showed a normal total cell number with neutrophilic alveolitis (65% neutrophils and 15% lymphocytes). Biopsy of the right upper bronchia by bronchoscopy was inconclusive: nonspecific inflammation. Once more no mediastinoscopy was performed. Smears for acid-fast bacilli were negative, all bacteriological cultures were negative and no tumor cells were found. Instead, the fungal culture for *Aspergillus* was positive. *Aspergillus precipitins* (IgG) levels were 80UA/mL. The presence of the colonized cavitation, negative tuberculin skin test, positive sputum exam, inflammatory signs, positive *Aspergillus precipitins* sustained the diagnosis of an acute form of *Aspergillois pneumonia*. Treatment with Itraconazole 200mg daily was initiated. The patient was discharged and a regular follow-up was decided.

The first follow-up visit performed in March 2014 found an asymptomatic patient, with no recurrence of haemoptysis and a SaO<sub>2</sub> of 97% in ambient air. Liver tests were normal. The 6 minutes walk test found a mild desaturation to 87% from the initial 95%, with a total distance of 411 m and dyspnea of 4 on the Borg scale. Pulmonary function tests identified severe impairment in diffusion capacity: FEV<sub>1</sub>/FVC ratio of 85%, FVC 1.75L (97% predicted), FEV<sub>1</sub> 1.5L (103% predicted), total lung capacity 3.51L (86%), residual volume 1.75L (92% predicted), MEF50 2.80 L/min (94% predicted), DLCO 1.47 ml/min/mmHg (25% predicted). The respiratory monitoring was continued every two months. In September 2014, the daily dose of antifungal treatment was doubled, obtaining this way the optimal Itraconazole levels. The patient remained asymptomatic, with good treatment tolerance. The sputum exams continued to be positive for *Aspergillus*, the precipitins levels remained elevated, the aspect on the HRCT-scan was unchanged (Figure 4). The presence of a cavity with a fungal ball, persistence of the fatigue and shortness of breath for more than 3 months and positive *Aspergillus* serology sustained the diagnosis of chronic cavitary pulmonary aspergillosis. The pulmonary fibrosis described on the HRCT in 2014, not observed earlier, sustains the hypothesis that CPA may progress to chronic fibrosing pulmonary aspergillosis.

One year follow up revealed an asymptomatic patient, with SaO<sub>2</sub> of 96% in ambient air, mild persistent systemic inflammation, ACE still in the normal range and stable pulmonary function tests: FEV<sub>1</sub>/FVC ratio of 83%, FVC 1.67L (92% predicted), FEV<sub>1</sub> 1.39L (95% predicted), DLCO 1.45 ml/min/mmHg (24% predicted). The desaturation persisted on the 6MWT. No improvement was noticed on the HRCT-scan (Figure 5). One year antifungal treatment managed to control the clinical symptoms, but it had no effect on the lung volumes. Due to the fibrosis extension and the high risk of bleeding, surgery was not considered a good option. Itraconazole treatment was changed with Voriconazole and the patient was referred to a specialized centre.



**Figure 3.** CT scan in February 2014: enlarged lymph nodes and apical fibrosis with right upper lobe cavity.

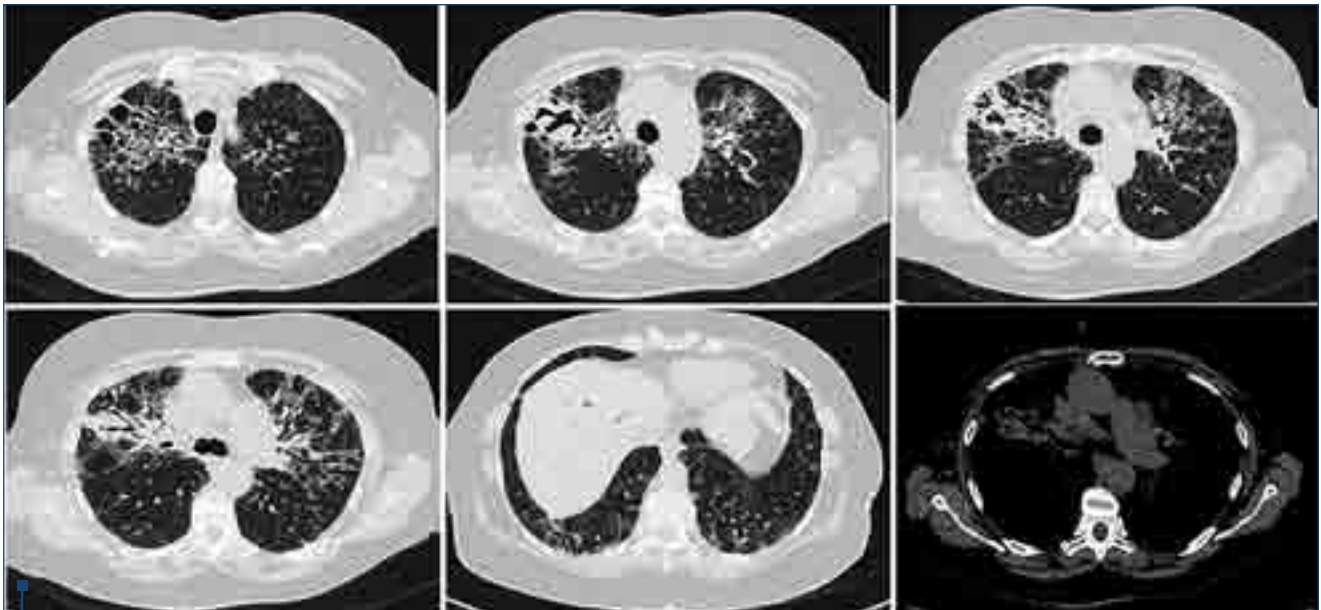


**Figure 4.** Evolution on CT scan during one year of treatment by Itraconazole

## Discussion

Sarcoidosis is an immune mediated granulomatous disease, with a wide range of radiological aspects which may mimic almost any disease. It has a predilection for women and the usually clinical presentation includes mild symptoms, as in our patient. Clinical features as dyspnea, dry cough and haemoptysis may suggest its progression. The positive diagnosis may not always require the histological confirmation in cases where clinical and paraclinical features are suggestive. In our case, sarcoidosis seems the most likely diagnosis, being sustained by clinical pre-

sentation (mild symptoms, spontaneous remission of arthritis) and by the presence of enlarged mediastinal lymph nodes, negative tuberculin skin test and negative serology for other systemic diseases. The follow-up included the monitoring of lung function, effort tolerance and progression on HRCT. The levels of angiotensin-converting enzymes were in normal range all the time, clinical presentation was stable and no degradation in CT evolution was noted. Perhaps the use of the new markers, as serum amyloid-A (SAA), as a predictor for pulmonary progression, and soluble interleukin-2 receptor associated



**Fig.5.** CT scan in 2015: stable fibrosis and cavitation.

with extra-pulmonary sarcoidosis would be more accurate indicators of disease evolution, with the possibility of changing the treatment<sup>7</sup>.

In patients with sarcoidosis, the evolution towards fibrosis may predict an opportunistic infection. In our case, the onset presented as an acute form of aspergillosis pneumonia. Under antifungal treatment the evolution was favourable. Sometimes, under proper therapy, patients may develop chronic aspergillosis, as our patient did. The arguments for the development of a chronic cavitary aspergillosis are the presence of the cavity in the right upper lobe, the persistence of symptoms for over 6 months, the positive serology for *Aspergillus* despite antifungal treatment. The evolution on HRCT between 2007 and 2014, with the appearance of fibrosis in 2014 and no improvement under proper therapy, may indicate the progression of *Aspergillus* infection toward chronic fibrosing pulmonary aspergillosis. Itraconazole was administered because it is considered to be the right choice for chronic aspergillosis due to its efficacy and minimal toxicity, compared to Amphotericin B<sup>8</sup>. Voriconazole may be considered as an alternative, but there are only few reports of this antifungal medication and chronic aspergillosis. Also, there is not a consensus regarding the treatment outcome and duration. Usually, Itraconazole is administered for 1-2 years, but relapses have been reported after this peri-

od. Regarding treatment efficacy, it was suggested that Itraconazole levels should be above 1250 ng/mL, but there are no guidelines to confirm this recommendation<sup>9</sup>. Surgical resection is not considered the first line of treatment, due to its high mortality and significant postoperative complications such as respiratory failure, bronchopleural fistulas, and pleural aspergillosis<sup>6,9</sup>. Surgical excision is reserved to symptomatic patients with active disease, despite adequate antifungal treatment<sup>6,8,9</sup>. In our patient, the risk of fatal haemorrhage was considered high, so the patient did not have surgery.

The particularity of the case consists in the association of sarcoidosis to a chronic aspergillosis in a patient with no known immunodeficiency.

### Abbreviations list:

- 6MWT** = 6 minute walk test
- ACE** = angiotensin-converting enzyme
- BMI** = body mass index
- CRP** = C reactive protein
- ER** = emergency room
- FEV1** = forced expiratory volume in the first second
- FVC** = forced vital capacity
- DLCO** = diffusion capacity
- HRCT-scan** = high-resolution computed tomography
- UECA** = units of angiotensin-converting enzyme ■

### References

1. Statement on sarcoidosis. Joint Statement of the American Thoracic Society (ATS), the European Respiratory Society (ERS) and the World Association of Sarcoidosis and Other Granulomatous Disorders (WASOG) adopted by the ATS Board of Directors and by the ERS Executive Committee, February 1999. *Am J Respir Crit Care Med.* 1999;160(2):736-755
2. Jamilloux I, Valeyre D, Lortholary O, et al. The spectrum of opportunistic diseases complicating sarcoidosis. *Autoimmun Rev.* 2015;14(1):64-74.
3. Kosmidis C, Denning DW. The clinical spectrum of pulmonary aspergillosis. *Thorax.* 2014. Epub ahead of print.
4. Tahuanty A, Pena AO, Soubani LS. *Aspergillus* Lung Disease in Patients with Sarcoidosis: A Case Series and Review of the Literature. *Lung.* 2011; 189:167-172.
5. Denning DW, Pleuvry A, Cole DC. Global burden of chronic pulmonary aspergillosis complicating sarcoidosis. *Eur Respir J.* 2013;41:621-626.
6. Denning DW, Riniotis K, Dobrashian R et al. Chronic Cavitary and Fibrosing Pulmonary and Pleural Aspergillosis: Case Series, Proposed Nomenclature Change, and Review. *Clinical Infectious Diseases.* 2003; 37(Suppl 3):S265-80.
7. Gungor S, Ozseker F, Yalcinsoy M et al. Conventional markers in determination of activity of sarcoidosis. *Int Immunopharmacol.* 2015 Jan 23;25(1):174-179.
8. Walsh TJ, Anaissie EJ, Denning DW et al. Treatment of aspergillosis: clinical practice guidelines of the Infectious Diseases Society of America. *Clin Infect Dis.* 2008; 46(3):327-360.
9. Nam HS, Jeon K, Um SW et al. Clinical characteristics and treatment outcomes of chronic necrotizing pulmonary aspergillosis: a review of 43 cases. *International Journal of Infectious Diseases.* 2010; 14(6): e479-e482.